Reports of Biochemistry & Molecular Biology
Vol.14, No.3, Oct 2025

Original article

www.RBMB.net

Evaluation of the Effects of Paraquat on the Expression of the *CYP17*, *CAT*, and *USP9Y* Genes, Sperm Parameters, and Histopathological Changes in the Testicular Tissue of BALB/C

Masoud Ghanbari[1], Zahra Babazadeh[2,3], Fatemeh Moradian*[4], Leila Beigom Hejazian[2,3]

Abstract

Background: This study aimed to investigate the harmful effects of paraquat (PQ) on sperm and testicular tissue and the protective effect of geraniol against the toxin.

Methods: In this study, 28 small white male mice were gavaged with PQ and geraniol for one month. Testicular tissue was removed to evaluate gene expression, sperm parameters and histopathological changes in testicular tissue.

Results: The relative gene expression results revealed that *CAT* and *CYP17* gene expression significantly increased in groups 3, 4, 5, 6, and 7 ($P< 0.001$). Additionally, the activity of the catalase enzyme increased. The expression level of the *USP9Y* gene increased in response to low concentrations of PQ. The sperm parameters, such as number, motility, and morphology, decreased after treatment with PQ. In the groups treated with PQ, the number of germinal layer cells was reduced and separated from the basement membrane. Malformed seminiferous tubules, thick myoepithelial cells, atrophy of Leydig cells, vascular congestion and fibrosis were observed. In the testicular tissue under the influence of two doses of PQ, the number and thickness of the epithelium of the seminiferous tubules, as well as the number of spermatozoa, were significantly reduced compared to the control. Additionally, the area of the seminiferous tubules and the number of spermatogonia and primary spermatocytes decreased slightly. Following geraniol treatment, a degree of improvement was observed in the levels of certain histopathological factors and all testicular tissue parameters.

Conclusion: PQ has adverse effects on testicular tissue and sperm, and geraniol has a protective effect against oxidants**.**

Keywords: Catalase, Fertility genes, Geraniol, PQ, Sperm.

Introduction

Infertility is defined as the inability to achieve pregnancy after one year of regular unprotected intercourse (1). Among the causesof infertility, 15% are related to genetic factors that can be divided into two groups:

chromosomal abnormalities and defects in a single gene. Any loss or gain of unusual rearrangements in genetic material at the

1: Department of Basic Sciences, Sari University of Agricultural Sciences and Natural Resources, Mazandaran, Iran.
2: Cellular and Molecular Biology Research Centre, Health Research Institute, Babol University of Medical Sciences, Babol, Iran.
3: Department of Anatomical Sciences, Faculty of Medicine and Cellular and Molecular Biology Research Centre, Babol University of Medical Sciences, Mazandaran, Iran.
4: Department of Basic Sciences, Sari University of Agricultural Sciences and Natural Resources, Mazandaran, Iran.
***Corresponding authors: Fatemeh Moradian; E-mail: f.moradian@sanru.ac.ir.**
Received: 20 Aug, 2025; Accepted: 1 Oct, 2025

chromosomal level is known as a chromosomal abnormality. It is one of the main genetic causes of male infertility (2). Paraquat (PQ), also known as Gramoxone (N, N'-dimethyl-4,4'-bipyridinium dichloride), is a chemical herbicide that is highly toxic and is used in some countries, including Iran. It is one of the most common herbicides used today, but it can cause fatal poisoning if ingested or inhaled. It is mainly used to manage the growth of weeds (3). PQ exposure over several generations in N2 nematodes causes a gradual decrease in fertility and a complete loss of fertile embryo production in the third generation (4). As reported in previous studies, the use of PQ poses risks to reproductive function (5). These studies have shown that the uptake of reactive metabolites of PQ through ion-mimetic processes in tissues severely interferes with transcription factors, including HSF2 and OVOL1, which are expressed in germ cells, as well as WT1, RHOX5, and SOX8, which are expressed in Sertoli cells and regulate sperm cell growth and maturation. Reduced sperm velocity and low motility can be due to the disruption of sufficient ATP production, which drives the propulsive movements of sperm. Low sperm count, high rates of non-motile sperm, and morphological abnormalities resulting from non-lethal exposure to PQ provide clear evidence that this toxin can cause rapid progression of infertility (6). According to a 2010 World Health Organization (WHO)report, the primary basis for diagnosing male infertility is through clinical assessment of sperm concentration, morphology, and motility WHO. Fathi et al., in their study on 14 male Wistar rats regularly fed with 50 mg/kg PQ for 7 days, observed a significant decrease in spermatocytes, spermatids, and Leydig cells, along with a significant increase in the structural parameters of the seminiferous tubules. They stated that PQ produces free radicals that have significant toxic effects on the number of spermatogenic cells and seminiferous tubule parameters (5). Previous studies have shown that PQ can cause a decrease in the weight of male reproductive organs in rats, such as the testes, epididymis, prostate, and seminal vesicles, as well as a reduction in the number of sperm, cells, and spermatogonia (7). PQ reduced the number of germ cells in BALB/c mice and caused them to shrink germ cells (8). A study was conducted on 25 male Wistar rats that received PQ dichloride at concentrations of 25, 50, 75, and 100% for 8 weeks. Histomorphometry of the testes showed that the seminiferous tubules were irregularly deformed and spermatogenesis had stopped. The number of sperm obtained from semen exposed to PQ dichloride showed a significant decrease; sperm morphology and sperm development were also negatively affected (9). In a study by D'Souza et al., PQ was administered to Sprague-Dawley rats once a day for five days, at intervals of 24-h hour intervals at 0, 6, 15 and 30 mg/kg. The results showed that sperm count decreased, sperm abnormalities increased, and sperm mortality increased; furthermore, motility was only affected at the 30 mg/kg dose on day 42 (10).

Reactive oxygen species (ROS) affect spermatogonia DNA; thus, the genomic integrity of spermatogenic cells may be compromised (11). Similarly, it has been reported that PQ is genotoxic in germ cells, in addition to being cytotoxic. Testicular tissue is susceptible to oxidative stress damage due to relatively higher levels of unsaturated fatty acids compared to other tissues (10).

PQ causes oxidative damage in cells. The mechanisms of PQ toxicity include the production of superoxide anions, which can lead to the formation of more toxic reactive oxygen species, such as hydrogen peroxide and hydroxyl radicals, as well as NADPH oxidation (3). Redox cycling and intracellular oxidative stress play critical roles in the mechanism of PQ-induced toxicity. Oxidative stress is an important factor affecting male fertility due to the very high rate of cell division and mitochondrial

oxygen consumption in testicular tissues. Consequently, testicular tissue and the male reproductive system are particularly susceptible to oxidative stress (8, 12). The development of an efficient antioxidant treatment from novel plant-derived compounds could provide a necessary antidote to reduce the toxic effects of PQ on reproductive function (13).

Geraniol is an acyclic monoterpene isoprenoid extracted from the essential oils of aromatic plants such as lemongrass, rose, and lavender. Geraniol exhibits a variety of medicinal activities, including antimicrobial, anti-inflammatory, antitumour, and antioxidant, as well as protective effects on the liver, heart, and nerves. These diverse properties make it a promising candidate for treating various diseases. Owing to its antioxidant properties and ability to regulate the activity of antioxidant enzymes, geraniol protects against and increases the degree of antioxidant defence against oxidative stress caused by toxins and increases the efficiency of cellular antioxidant defence (14). Oxidative stress and reactive oxygen species (ROS) are generated from both endogenous and environmental sources, which may lead to defects in spermatogenesis and male infertility. Antioxidant-related genes, including catalase (CAT), glutathione peroxidase (GPX), glutathione S-transferase (GST), nitric oxide synthase (NOS), nuclear factor erythroid 2-related factor 2 (NRF2) and superoxide dismutase (SOD), play important roles in normal sperm production and function (15). Catalase is an important antioxidant enzyme that breaks down hydrogen peroxide into water and oxygen (16). This enzyme can reduce the cellular oxidative stress caused by the use of pesticides in the cell. Owing to their low levels in the sperm cytoplasm, sperm cytoplasm, these antioxidant enzymes cannot adequately repair oxidative damage (17). Azoospermia, defined as the absence of sperm in the semen, is a severe form of male infertility. The azoospermia factor (AZF) genes are encoded by the AZF region on the Y chromosome (Yq11) in males. Deletions in this region are associated with the inability to produce sperm (18, 19, 20). The first gene identified in the AZFa region, whose absence has been observed in several infertile patients, is the *USP9Y* gene (ubiquitin-specific protease 9 on chromosome Y), previously known as DFFRY. The cytochrome P450c17α (*CYP17* gene), located on chromosome 10q24.3, encodes the cytochrome P450c17α hydroxylase enzyme, which is involved in steroid hormone biosynthesis (21). A deficiency in the 17α-hydroxylase enzyme can lead to disorders related to the function of endocrine glands, including the gonads (ovaries and testes) and the adrenal glands. The gonads regulate sexual development before birth and during puberty, and they are important for reproduction and the production of sex steroid hormones (22). This enzyme also plays a role in xenobiotic metabolism. In the present study, the effects of the fertility-related genes CAT, CYP17, and USP9Y, as well as on histopathological parameters, testicular tissue alterations, and sperm parameters and morphology, were evaluated in fertile male mice.

Materials and Methods

Animals

Twenty-eight small BALB/c mice, aged 6–8 weeks and weighing 20–30 g, were used. The mice were randomly divided into seven groups of 4 each. Each group of animals was housed in separate cages in the animal facility of Babol University of Medical Sciences and maintained at a temperature of 23 ± 3 °C, with a 12-hour light/dark cycle. The mice had ad libitum access to food and water.

The animals were divided into seven groups (n= 4 per group) (Table 1).

Table 1. Experimental groups, administered compounds, and dosing regimens in male BALB/c mice (n = 4 per group).

Group	Designation	Treatment / Compound	Treatment / Compound	Administration Route & Schedule
1	Negative Control	Sterile normal saline	400 µL	IP; 5 consecutive days/week for 1 month
2	Oil (Vehicle Control)	Sesame oil	400 µL	IP; 5 consecutive days/week for 1 month
3	Geraniol (J100)	Geraniol	100 mg/kg	Oral gavage; 5 consecutive days/week for 1 month
4	PQ 0.5	Paraquat (PQ)	0.5 mg/kg (400 µL)	IP; 5 consecutive days/week for 1 month
5	PQ 2.5	Paraquat (PQ)	2.5 mg/kg (400 µL)	IP; 5 consecutive days/week for 1 month
6	J + PQ 0.5	Geraniol + Paraquat	100 mg/kg + 0.5 mg/kg (400 µL)	Co-administered via oral gavage and IP; 5 consecutive days/week for 1 month
7	J + PQ 2.5	Geraniol + Paraquat	100 mg/kg + 2.5 mg/kg (400 µL)	Co-administered via oral gavage and IP; 5 consecutive days/week for 1 month

*PQ, Paraquat; J, Geraniol. All solutions were prepared daily before administration. The total volume for all oral gavage treatments was kept uniform across groups.

All experimental protocols in this study were reviewed and approved by the Institutional Animal Care and Ethics Committee of the Faculty of Animal Sciences, Sari Agricultural Sciences and Natural Resources University (Approval No. IR. SANRU.03-1403-02), and all procedures adhered to internationally recognized standards for the care and use of laboratory animals. All animals were euthanized at the end of the experimental period in strict accordance with internationally recognized guidelines for laboratory animal welfare. Mice were first deeply anesthetized via intraperitoneal administration of ketamine and xylazine (a 1:2 v/v mixture of ketamine hydrochloride and xylazine hydrochloride), and the loss of pedal and corneal reflexes was used to confirm a surgical plane of anesthesia.

Preparation of geraniol and PQ solutions

Geraniol (98% purity) was purchased from Sigma-Aldrich (USA). Geraniol was prepared as a solution in sesame oil at a final concentration of 100 mg/kg. Paraquat (PQ) (Kimia Azma Jam Company, Iran) was dissolved in normal saline to prepare working solutions at doses of 0.5 mg/kg and 2.5 mg/kg for animal treatment.

RNA extraction from testicular tissue

Total RNA was extracted using the total RNA extraction kit (Parstous, Iran) according to the manufacturer's instructions and in the following manner. Frozen testicular tissue was finely minced into small fragments, and 750 µl of RL buffer was added. The resulting cell suspension was transferred to a clean 1.5 ml microcentrifuge tube and incubated at room temperature for 5 min. Subsequently, 500 µl of chloroform was added, and the tube was shaken for 15 seconds, followed by a 3-min incubation at room temperature. The mixture was then centrifuged at 18,000 x g for 12 min at 4 °C. After phase separation, 400 µl of the upper aqueous phase was carefully collected and transferred to a new microcentrifuge tube. An equal volume (400 µl) of 70% ethanol was added and mixed thoroughly. The mixture was transferred to a spin column provided in the kit and centrifuged at 18,000 x g for 2 min. The flow-through in the collection tube was discarded. Then, 700 µl of PW buffer was added to the column and centrifuged at 18,000

x g for 2 min. The flow-through was discarded, and 500 µl of PW buffer was added again to the column, followed by centrifugation under the same conditions. Next, the spin column was placed into a new 1.5 ml microcentrifuge tube, and 50 µl of DEPC-treated water was added to elute the RNA. The column was incubated at room temperature for 3 min and then centrifuged at 18,000 x g for 1 min. The spin column was discarded, and the purified RNA was stored at -80 °C until further use.

cDNA synthesis

Complementary DNA (cDNA) was synthesized using the Easy™ cDNA Synthesis Kit (Parstous, Iran). The cDNA synthesis reaction was prepared according to the manufacturer's instructions. The prepared reaction mixture was incubated at 25 °C for 10 min, followed by 60 min at 47 °C. To inactivate the enzym, the microtubes were then incubated at 85 °C for 5 min. Upon completion of the reaction, 2 µl of the synthesized cDNA was used to verify the quality and quantify the concentration using a spectrophotometer. To verify the accuracy of cDNA synthesis and quantify the concentration, a spectrophotometer was used to measure the optical absorbance at 260 and 280 nm.

Design of specific primers

The sequences of the *USP9Y*, *CYP17*, *CAT* and *HPRT* (used as a reference gene) genes were extracted from the NCBI database.

Multiple sequence alignment was performed to identify highly conserved regions. Fully conserved gene regions free of reported single nucleotide polymorphisms (SNPs) were selected for primer targeting. The primers were designed using Gene Runner software (version 6.5.52). The primer sequences (5′ to 3′) were as follows:

- *HPRT* (forward, F): ATTGATGCCGAGGATTTGGA, reverse (R): ACTCTATAGCCCCCCTTGA;
- *CAT* (F): GCCAGCGACCAGATGAAGCAGT, (R): GGTGACCTCAAAGTATCCAAAAGCA;
- *CYP17*(F): GGGAACTTGTGGGTCTCTTGCTG, (R): GCGAAHAGAATAGATGGGACCATAC;
- *USP9Y*(F): GCTCACAGAATTCATAATGCACTTAAAG, (R): CTGTGATGTTCCAAGGAAGAGCTGA.

Quantitative real-time PCR

Real-time PCR reactions were conducted in a total volume of 15 µl using the YTA SYBR Green qPCR Master Mix (2X) kit (Yekta Tajhiz Azma Company, Iran). The amplification was carried out on a Rotor-Gene 3000 system (Corbett Research, Australia). The thermal cycling protocol consisted of an initial denaturation at 94 °C for 5 min, followed by 35 cycles of denaturation at 94 °C for 1 min, annealing at 60 °C for 1 min, and extension at 72 °C for 1 min, with a final extension step at 72 °C for 5 min. To assess the efficiency and reliability of the qRT-PCR reactions, a standard curve was generated using serial dilutions of a standard sample. Cycle threshold (C_t) values were plotted against the logarithm of the corresponding concentrations to construct the standard curve. Each reaction series included a housekeeping gene as an internal control to ensure consistent normalization across samples. The expression levels of the target genes were normalized to the internal control gene by calculating the ratio of their expression values. The comparative $2^{-\Delta\Delta Ct}$ method was employed to determine relative gene expression levels, with HPRT serving as the internal reference gene for normalization.

Data analysis

Relative gene expression levels were calculated using the $2^{-\Delta\Delta Ct}$ method. Statistical analysis was performed using IBM SPSS Statistics software (version 22.0). Data were analyzed using one-way analysis of variance (ANOVA), followed by Duncan's multiple range test for post-hoc comparisons. A significance threshold of $P< 0.001$ was applied to determine statistically significant

differences between the experimental groups.

Catalase (CAT) activity assay

After each mouse was anesthetized, blood was immediately collected from the right ventricle. The blood sample was transferred into a Falcon tube containing EDTA to prevent coagulation. Then, the samples were centrifuged at 1000 x g for 10 min, and the plasma was separated from the red blood cells. To measure catalase activity, the reaction was carried out in a quartz cuvette containing 1500 µl of 10 mM potassium phosphate buffer (pH 7.0), 10 µl of plasma, and 10 µl of H_2O_2 as a substrate. After 3 min, the rate of hydrogen peroxide decomposition was measured using a spectrophotometer (Shimadzu, Japan) at a wavelength of 240 nm. The total activity was calculated and expressed as µmoles of H_2O_2 (OD_{240})/3 min using a molar extinction coefficient for H_2O_2 of 43.6 $M^{-1}cm^{-1}$.

Histopathology of testicular tissue

The right testis was removed, and the epididymal ducts and vas deferens were separated. The testis was subsequently divided into six equal parts using a ruler. Tissue sections from the testis were carefully separated and individually embedded in rectangular moulds filled with molten paraffin to ensure proper orientation and preservation for histological analysis.

The paraffin blocks were kept at room temperature until they had hardened completely. Five-micrometre sections were cut from each paraffin block via a microtome (Lietz, Germany)., The first two sections and the eighth section were selected. The sections were placed in an oven at 60 °C for 30- 45 min to melt the paraffin around the samples and then stained with hematoxylin and eosin (H&E) or Masson's trichrome. Microscopic images of the prepared tissue slides were captured using an optical microscope (Olympus) equipped with a digital camera (Canon) at magnifications of 4×, 10×, and 40×. Images were taken systematically from uniformly spaced regions across the slides. Quantitative data were extracted and analyzed using Zist Lab software (version 1.97) and ImageJ analysis software.

Histomorphometry Analysis

The epithelial thickness of the seminiferous tubules was measured at four equidistant points along opposing angles using images captured at 4× magnification. The cross-sectional area of the seminiferous tubules was measured using Zist Lab software (version 1.97) at 10× magnification. Tubular circumference was manually traced, and the data were subsequently compiled and analyzed using GraphPad Prism (version 9.0). To quantify the number of seminiferous tubules, micrographs were captured from various regions of each histological slide at 4× magnification. Approximately 200 images were analyzed per experimental group to ensure representative sampling. For cellular quantification, including the number of spermatogonia, primary spermatocytes, spermatids, and spermatozoa, high-resolution images were obtained at 40× magnification. Cell counting was performed using ImageJ software. Spermatogonia were identified as small, round cells with densely stained nuclei located in the basal layer of the seminiferous epithelium. Primary spermatocytes were distinguished by their larger size and lighter euchromatic nuclei. Spermatids were characterized by their round nuclei and prominent nucleoli, while spermatozoa were recognized by their elongated, condensed nuclei.

Examination of sperm parameters

The right testis was removed immediately through an incision in the mouse's abdomen and washed in distilled water. Then, the tail of the epididymis and the beginning of the right testis were removed and placed in small dishes containing 10 ml of Ham's F10 solution (Ham's F10 was placed in a 37 °C incubator for approximately 1 h earlier). The tissue was crushed with the two insulin needles and incubated at 37 °C for 30 min to allow the sperm to emerge from the epididymis and vas deferens and disperse into the culture medium. Then, a drop of the sperm suspension was

loaded onto a Neubauer hemocytometer, and the sperm count and motility were determined under a light microscope.

Evaluation of sperm morphology

Sperm smear slides (12 slides per group) were prepared from the sperm suspension in Ham's F10 medium. After air-drying, the smears were fixed in 70% ethanol and stained using the Papanicolaou method. Sperm morphology was then evaluated across four different fields per slide using a light microscope (Olympus EX, Japan) at 40× magnification.

Results

Relative expression levels of the CAT, CYP17, and USP9Y genes

The relative expression level of the *CAT* gene increased by 1.1, 1.7, 2.1, 1.5, 2.8 and 2.4 -fold in Oil, J100, PQ 0.5, PQ 2.5, J+PQ 0.5, and J+PQ 2.5 groups, respectively, compared to the negative control group. Gene expression in all treatment groups, except for the Oil group (vehicle control), was significantly higher than that in the control group ($P < 0.05$). Furthermore, CAT expression significantly differed between the PQ 0.5 and J+PQ 0.5 groups, as well as between the PQ 2.5 and J+PQ 2.5 groups ($P < 0.0001$), indicating that the addition of geraniol significantly altered catalase gene expression.

The relative expression level of the *CYP17* gene increased by 1.1, 4.9, 4.5, 4.5, 9.9 and 5.4 - fold in the Oil, Oil, J100, PQ 0.5, PQ 2.5, J+PQ 0.5, and J+PQ 2.5 groups, respectively. CYP17 expression in all these groups, except for the Oil group, differed significantly from the control group ($P < 0.001$). A significant difference was observed between the PQ 0.5 and J+PQ 0.5 groups ($P < 0.0001$); however, the difference between the PQ 2.5 and J+PQ 2.5 groups did not reach statistical significance.

The relative expression level of the *USP9Y* gene in the J100, PQ 0.5, and J+PQ 0.5 groups increased by 1.66, 1.05, and 1.2-fold, respectively. Across all experimental groups, USP9Y gene expression showed no statistically significant differences compared to the control group. Similarly, no significant differences were observed when comparing the PQ 0.5 group to the J+PQ 0.5 group, or the PQ 2.5 group to the J+PQ 2.5 group ($P< 0.001$) (Fig. 1).

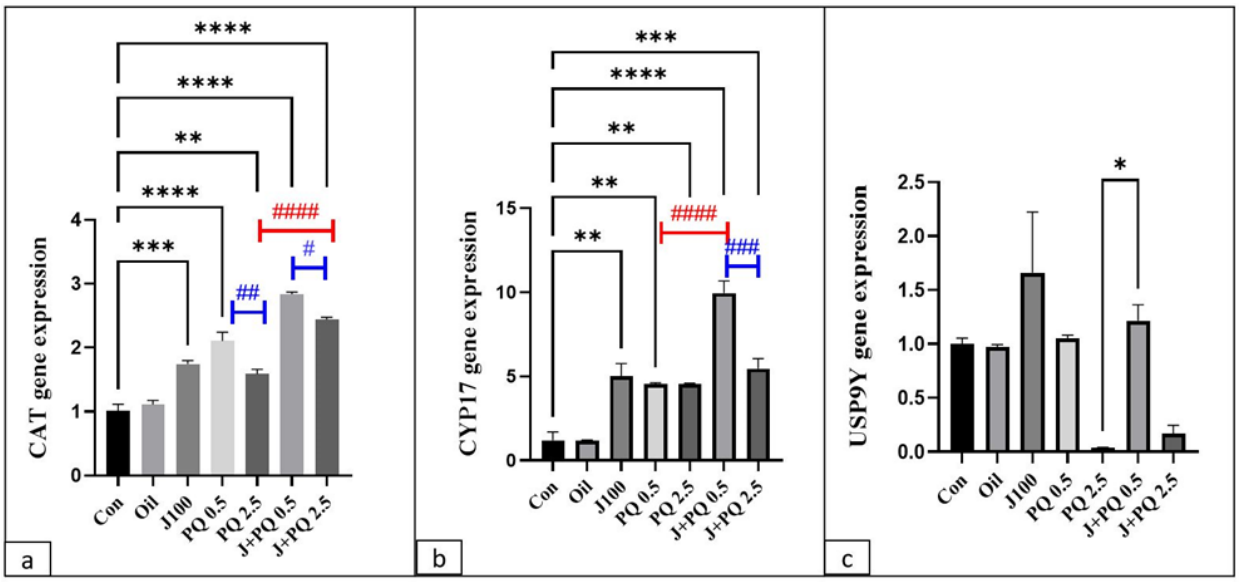

Fig. 1. Expression diagram of the CAT, CYP17 and USP9Y genes in different groups. Relative expression levels of (a) CAT, (b) CYP17, and (c) USP9Y genes across different treatment groups: Control (Con), Oil, J100, PQ 0.5, PQ 2.5, J+PQ 0.5, and J+PQ 2.5. Data are presented as mean ± SEM. Statistical analyses were performed using ordinary one-way ANOVA followed by Tukey's post hoc test for multiple comparisons. Asterisks (*, **, ***, ****) indicate significant differences compared with the control group. Hashtags (#, ##, ###) indicate significant differences between the combination groups (J+PQ) and the corresponding single-treatment groups (PQ) and among treatments. A p-value < 0.05 was considered statistically significant. *, # ($P \leq 0.05$); **, ## ($P \leq 0.001$); ***, ### ($P \leq 0.0005$); and ****, #### ($P \leq 0.0001$).

The amount of catalase activity

The amount of catalase activity increased by 1.05, 2.7, 2.9, 2.7, 3.**,3** and 3.1 times in groups Oil, J100, PQ 0.5, PQ 2.5, J+PQ 0.5, and J+PQ 2.5, respectively (Fig. 2). The catalase activity in all the groups except the Oil group was significantly different from that in the control group (P< 0.0001).

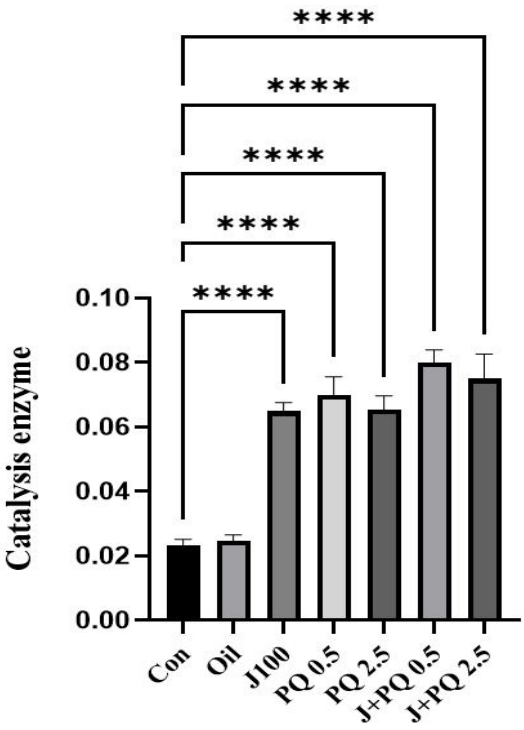

Fig. 2. The catalase activity in different groups. Catalase activity levels across different treatment groups: Control (Con), Oil, J100, PQ 0.5, PQ 2.5, J+PQ 0.5, and J+PQ 2.5. Data are presented as mean ± SEM. Statistical analyses were performed using ordinary one-way ANOVA followed by Tukey's post hoc test for multiple comparisons. Asterisks (****) indicate significant differences compared with the control group (P < 0.0001). All groups, except the oil group, were significantly different from the control group. A p-value < 0.05 was considered statistically significant.

Histopathological changes in testicular tissue

Histopathological alterations in cell and tissue morphology were investigated across the different experimental groups (Table 2). No histopathological changes were observed in the control or vehicle control (sham) groups. In the J100 group, only mild vascular congestion was detected. In the PQ 0.5 group, pathological changes were observed in all histopathological parameters except for peritubular myoid cells. In the PQ 2.5 group, degenerative changes were observed across all histopathological parameters. No histopathological alterations were observed in the J+PQ 0.5 group, demonstrating that treatment with geraniol attenuated the toxic effects of PQ. In the J+PQ 2.5 group, pathological changes were observed in all histopathological parameters except for peritubular myoid cells and Leydig cell atrophy (Figs. 3 & 4).

The number of seminiferous tubules in the different groups was counted from micrographs captured at 10× magnification (Fig. 5). A significant decrease was observed in the PQ 0.5 and PQ 2.5 groups compared with the control group (P < 0.0001). The cross-sectional area and epithelial thickness of the seminiferous tubules were assessed across the experimental groups (Figs. 6 and 7). In terms of cross-sectional area, only the PQ 2.5 and J+PQ2.5 groups showed a significant difference compared to the control group (P < 0.0001). The epithelial thickness of the seminiferous tubules in all groups, except for the Oil and J+PQ 0.5 groups, was significantly reduced compared to that in the control group (P < 0.001). The numbers of primary spermatocytes, spermatogonia, spermatids and spermatozoa in the different groups were counted (Fig. 8). No significant difference was observed in the number of spermatogonia between the treatment groups and the control group, except for the J+PQ 0.5 group (P < 0.05). The number of primary spermatocytes in the PQ 2.5 and J+PQ 2.5 groups was significantly different from that in the control group (P < 0.05). The number of spermatids across all experimental groups except the J+PQ 0.5 and J+PQ 2.5 groups (P < 0.001) was not significantly different from that in the control group. The number of spermatozoa in all groups, except for Group 2 (vehicle control), differed significantly from that in the control group (P < 0.0001).

The sperm parameters and morphology

Two types of sperm motility—progressive and non-progressive were evaluated (Table 3). Non-progressive movement included grades 0,

1, and 2, which characterized sperm that were immotile, exhibited in situ movement without forward or backward progression, or displayed circular or zigzag trajectories, respectively. Progressive motility included grades 3 and 4, which denoted sperm moving forward linearly at a moderate speed or swimming rapidly with highly rapid flagellar beats. The prevalence of normal and abnormal sperm morphology across the different groups was subsequently quantified. The observed abnormal sperm phenotypes included leaf-shaped heads, bent necks, double heads, headless sperm (pinheads), bent tails, and broken sperm. The median morphology scores for normal sperm across the control, Oil, J100, PQ 0.5, PQ 2.5, J+PQ 0.5, and J+PQ 2.5 groups were 7, 6, 6, 6, 5, 5, and 6, respectively. Conversely, the abnormal sperm scores within the same respective groups were 1, 2, 4, 5, 7, 6, and 7.

Table 2. Histopathological changes in testicular tissue.

Histopathological changes	Control	Oil	J100	PQ 0.5	PQ 2.5	J+PQ 0.5	J+PQ 2.5
Reduction of germ layer cells	-	-	-	++	+++	-	++
Germinal epithelium Separation	-	-	-	++	+++	-	+
Destruction of germ layer cells	-	-	-	++	+++	-	+
Deformed seminiferous tubules	-	-	-	++	+++	-	++
Thickness of myoepithelium	-	-	-	-	+	-	-
Atrophy of Leydig cell	-	-	-	+	++	-	-
Vascular congestion	-	-	+	++	+++	-	++
Fibrosis	-	-	-	+	++	-	+

(-) does not have; (+) mild; (++) moderate; (+++) severe.

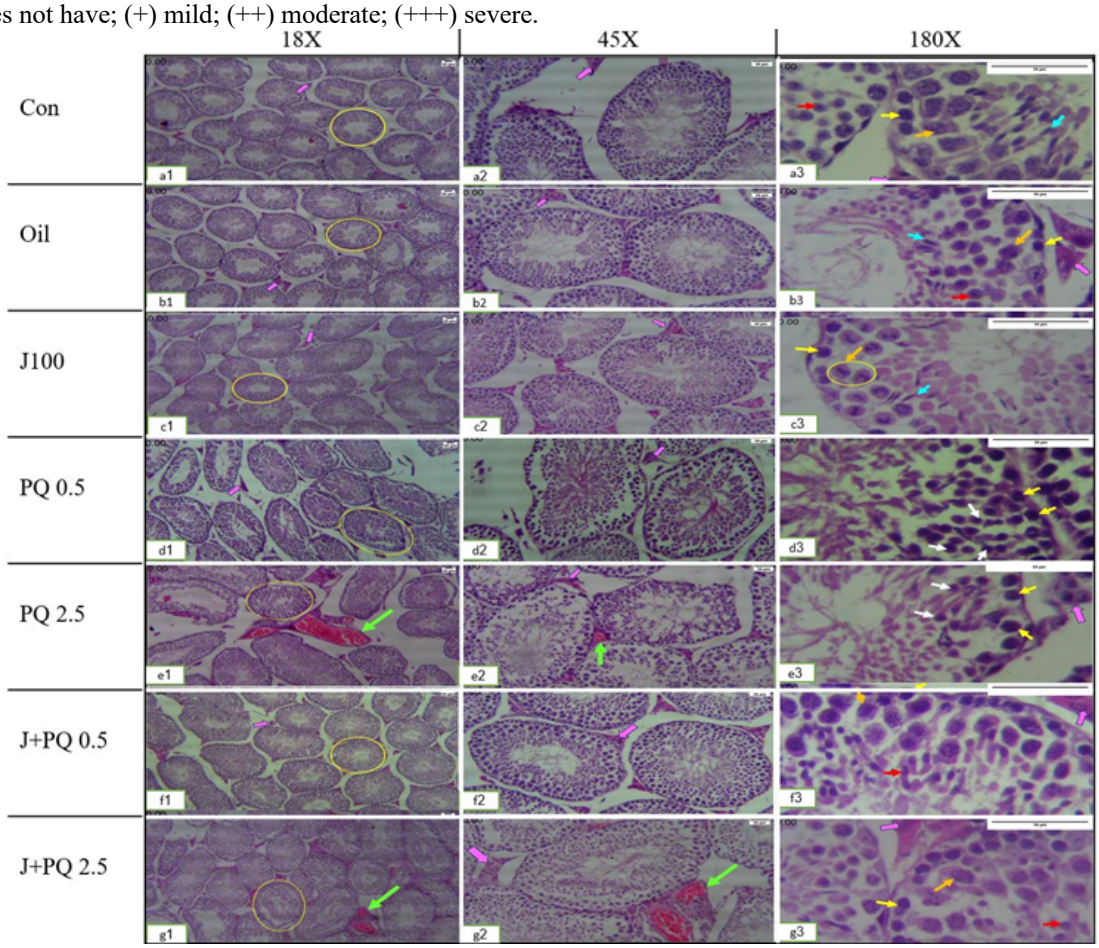

Fig. 3. Histopathological photograph. a: control, b: Oil, c: J100, d: PQ 0.5, e: PQ 2.5, f: J+PQ 0.5, g: J+PQ 2.5. The magnification of a1-g1: (4.5×4x) a2-g2: (4.5×10x) a3-g3: (4.5×40x). Yellow circles: seminiferous tubules; green arrows: congested; pink arrows: Leydig cells; yellow arrows: spermatogonia; red arrows: spermatid cells; blue arrows: spermatozoa

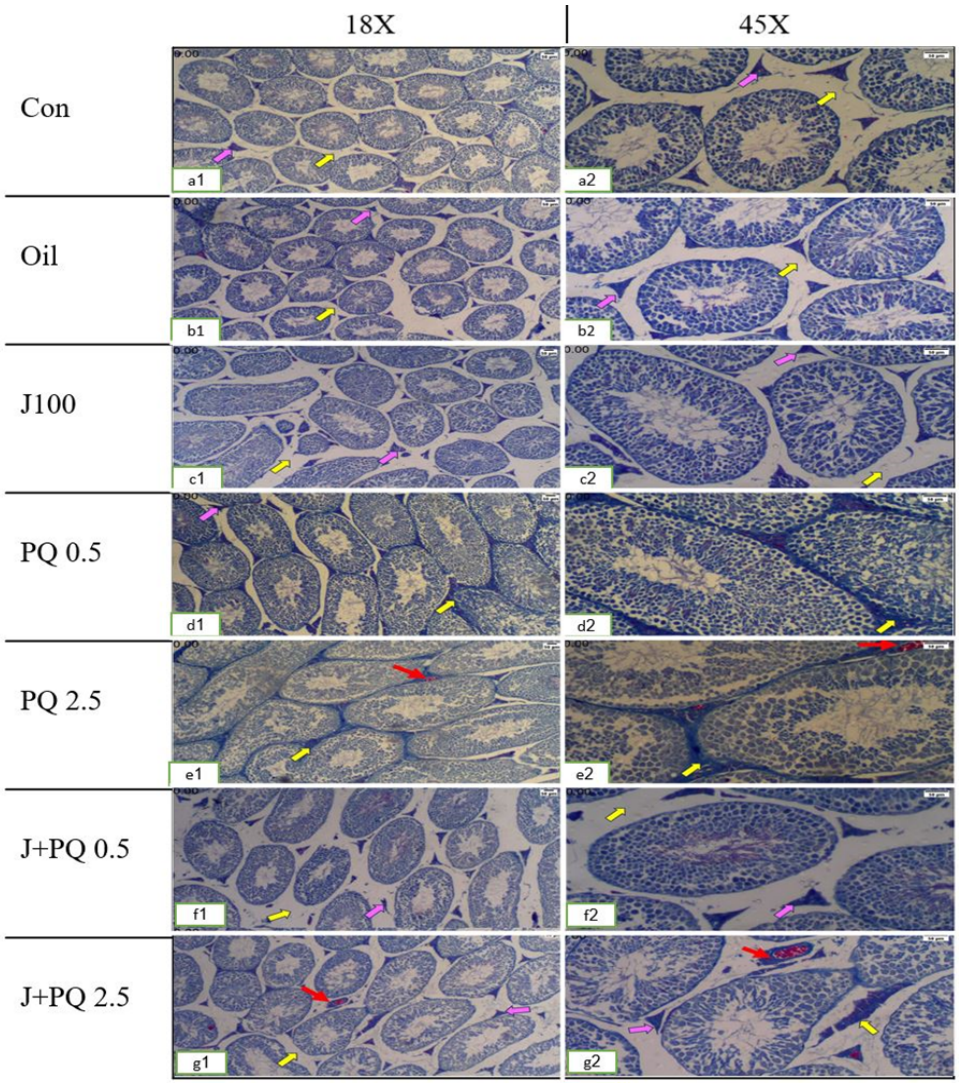

Fig. 4. Fibrotic photography of the testis via Masson's trichrome staining: a: control, b: Oil, c: J100, d: PQ 0.5, e: PQ 2.5, f: J+PQ 0.5, g: J+PQ 2.5. The magnification of a1-g1: (4.5×4x) a2-g2: (4.5×10x). Pink arrows: Leydig cells; yellow arrows: fibrotic area; red arrows: congestion. The magnification of the camera lens was 4.5. The scale bar was 50 µm.

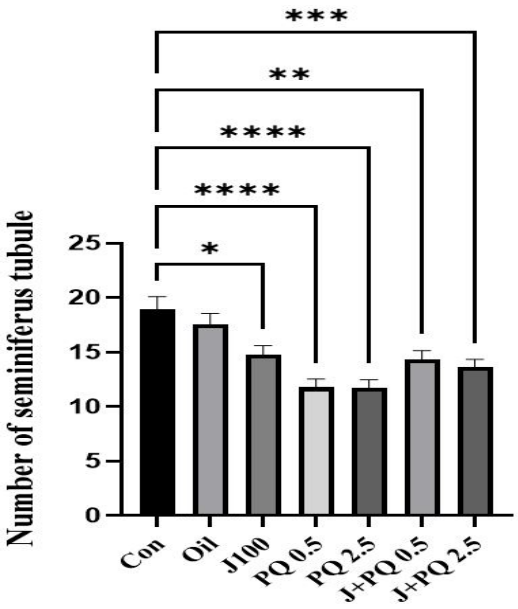

Fig. 5. The number of seminiferous tubules in the groups. The number of seminiferous tubules across different treatment groups: Control (Con), Oil, J100, PQ 0.5, PQ 2.5, J+PQ 0.5, and J+PQ 2.5. Data are presented as mean ± SEM. Statistical analyses were performed using ordinary one-way ANOVA followed by Tukey's post hoc test for multiple comparisons. The PQ 0.5 and PQ 2.5 groups showed significant differences compared with the control group. A p-value < 0.05 was considered statistically significant. * ($P \leq 0.05$); ** ($P \leq 0.001$); *** ($P \leq 0.0005$); and **** ($P \leq 0.0001$).

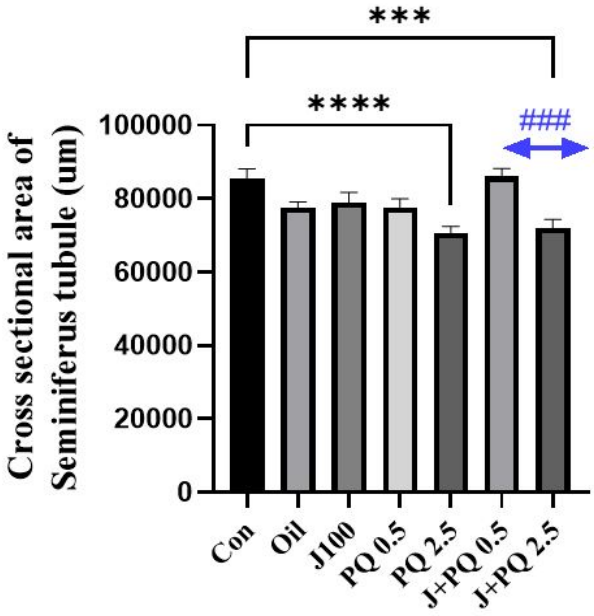

Fig. 6. Graph showing the areas of the seminiferous tubules in the different groups. The areas of the seminiferous tubules across different treatment groups: Control (Con), Oil, J100, PQ 0.5, PQ 2.5, J+PQ 0.5, and J+PQ 2.5. Data are presented as mean ± SEM. Statistical analyses were performed using ordinary one-way ANOVA followed by Tukey's post hoc test for multiple comparisons. The PQ 2.5 and J+PQ2.5 groups (Group 5 and 7) showed a significant difference compared with the control group. Among treatments, significant differences were observed between J+PQ5 and J+PQ2.5. A p-value < 0.05 was considered statistically significant. ***, ### ($P \leq 0.0005$); and **** ($P \leq 0.0001$).

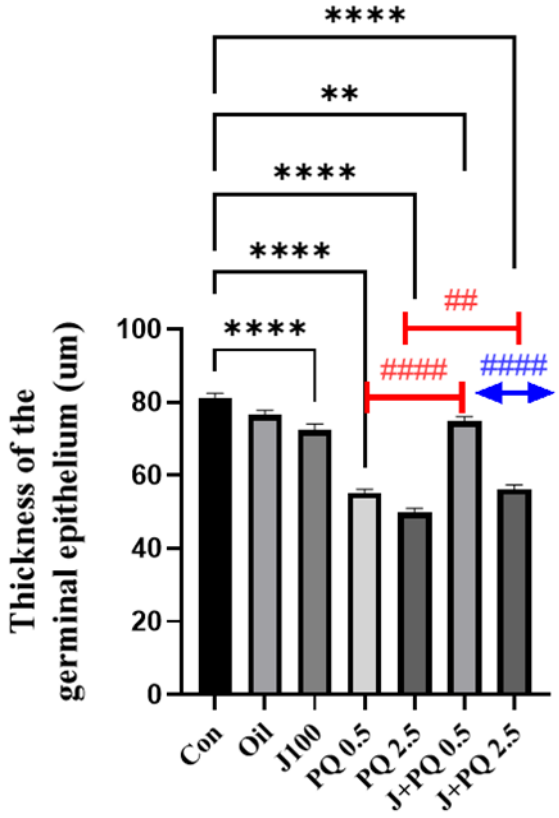

Fig. 7. The thickness of the germinal epithelium of the seminiferous tubules in the different groups. Control (Con), Oil, J100, PQ 0.5, PQ 2.5, J+PQ 0.5, and J+PQ 2.5. Data are presented as mean ± SEM. Statistical analyses were performed using ordinary one-way ANOVA followed by Tukey's post hoc test for multiple comparisons. All groups, except the oil group (Group 2), showed a significant difference compared with the control group. A p-value < 0.05 was considered statistically significant. **, ## ($P \leq 0.001$); and ****, #### ($P \leq 0.0001$).

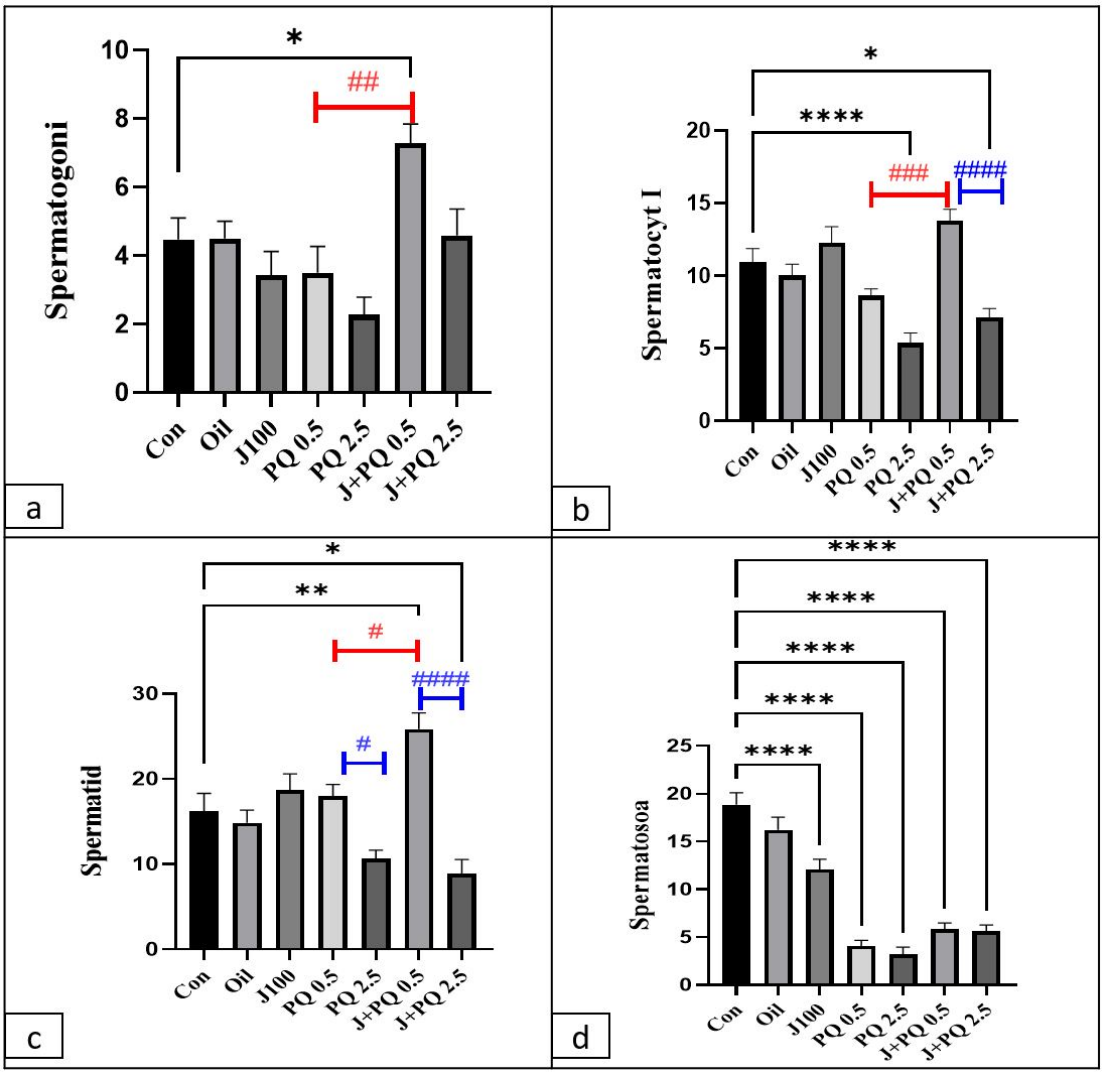

Fig. 8. Effects of different treatments on the numbers of (a) spermatogonia, (b) spermatocytes, (c) spermatids, and (d) spermatozoa. Data are presented as mean ± SEM. Statistical analyses were performed using ordinary one-way ANOVA followed by Tukey's post hoc test for multiple comparisons. (a) No significant difference was observed in the number of spermatogonia between the treatment groups and the control group, except for the J+PQ 0.5 group. (b) The number of primary spermatocytes in the PQ 2.5 and J+PQ 2.5 groups was significantly different from that in the control group. (c) The J+PQ 0.5 and J+PQ 2.5 groups differed significantly from the control. (d) All groups except the oil group differed significantly from the control. A p-value < 0.05 was considered statistically significant. *, # ($P \leq 0.05$); **, ## ($P \leq 0.001$); ***, ### ($P \leq 0.0005$); and ****, #### ($P \leq 0.0001$).

Table 3. Sperm parameters.

Grade / Group	0	1	2	3	4	Sperm count (10^6)
Control	7	4	4	4	5	24,000,000
The oil	8	4	2	4	4	22,000,000
J100	7	4	4	4	3	22,000,000
PQ 0.5	8	5	4	2	2	21,000,000
PQ 2.5	8	4	3	2	1	18,000,000
J+PQ 0.5	8	4	2	2	1	17,000,000
J+ PQ 2.5	9	3	2	2	1	17,000 000

The nonprogressive category contains grades 0, 1 and 2; the progressive category contains grades 3 and 4.

Discussion

The causes of infertility in males include infection, scrotal injury or trauma, exposure to toxins, anatomical variance, chromosomal and genetic abnormalities, systemic diseases, and the presence of anti-sperm antibodies (2, 23). The present study investigated the expression of three genes involved in male infertility in male BALB/c mice treated with PQ and geraniol. The results revealed that the level of *CAT* gene expression increased significantly in all treatment groups, and the gene expression in the groups that received only PQ differed significantly from that in the groups that received both PQ and geraniol. These findings indicate that geraniol can upregulate the expression of antioxidant enzymes even in the presence of toxins. Additionally, the activity of the antioxidant enzyme catalase was significantly greater in the different treatment groups than in the control group. The concurrent increases in CAT gene expression and catalase enzyme activity confirm that PQ and geraniol co-administration were able to induce this enzyme both at the gene level and at the protein level. Catalase activity and geraniol treatment mitigate the oxidative stress caused by pesticides in cells. Rubio-Riquelme reported that catalase plays an important role in male fertility, as its antioxidant activity prevents excessive oxidative stress, which can otherwise damage sperm parameters and thus reduce fertility (24). Alizadeh et al. reported that PQ induces oxidative stress, which subsequently activates endogenous antioxidant enzymes (25).

PQ is absorbed through the bloodstream and distributed to almost all organs and tissues of the body. PQ is not metabolized but is converted into an unstable free radical that is then re-oxidized to form a cation and produce the superoxide anion (9). Most of the problems that threaten the health of the reproductive system, especially testicular function, are related to oxidative stress caused by free radicals. For the proper functioning of testicular cells, it is essential to establish a balance between production and elimination of free radicals. If the biological defense mechanism of the testis cannot detoxify or repair the adverse effects of free radicals, testicular cells and tissue will be seriously damaged. Part of the body's antioxidant defence system, called the preventive antioxidant system, includes antioxidant enzymes such as SOD, CAT, and GPX (12). Semen is known to contain a range of antioxidant compounds that play a critical role in protecting spermatozoa from oxidative stress. Notably, the antioxidant capacity of semen is significantly higher in fertile males compared to infertile males, highlighting the importance of oxidative balance in male reproductive health (12). Given that endogenous antioxidants produced by the body are not able to neutralize all free radicals, the use of antioxidant supplements can play an important role in increasing the body's capacity to fight free radicals.

Sperm cytoplasmic antioxidant enzymes cannot repair oxidative stress-induced damage because their concentration within the sperm cytoplasm is low; however, antioxidant enzymes systemically play a protective role in cells (17). The serum levels of lactate dehydrogenase were decreased in male Wistar rats exposed to PQ (25). Black et al. investigated the increase in oxidative stress and the expression of antioxidant enzymes in mouse keratinocytes after exposure to PQ and reported that PQ caused oxidative stress in these cells, leading to an increase in the expression of antioxidant enzyme-encoding genes (26). In addition to the ability of antioxidant enzymes to neutralize oxidative stress, essential oils from certain medicinal plants exhibit similar properties and enhance the efficacy of endogenous antioxidant enzymes. The medicinal properties of geraniol include anti-inflammatory and antioxidative effects that can protect organs from oxidative damage (27). Pavan et al. investigated the pharmacological parameters of geraniol, including its bioavailability and multiple effects on liver antioxidant enzymes and xenobiotic-

metabolizing enzymes, and reported that in rats treated with geraniol for 4 weeks, the antioxidant defense capacity increased, with no signs of hepatotoxicity (28). There was a significant increase in CYP17 gene expression in all treatment groups. The CYP17 gene expression in the group that received PQ at a lower dose was significantly different from that in the group that received PQ and geraniol simultaneously. The results showed that geraniol can increase CYP17 gene expression in the presence of the toxin. The increase in CYP17 gene expression confirms that geraniol and PQ are capable of inducing this gene. This gene is one of the most important genes involved in fertility and plays a role in the production of sex hormones and reproduction; in addition, it also plays a role in xenobiotic metabolism (22). In rats treated with a relatively high dose of geraniol, the enzyme activity of CYP450, a xenobiotic-metabolizing enzyme, was increased (28). The relative expression level of the USP9Y gene increased in response to treatment with geraniol alone or in the presence of low concentrations of PQ and geraniol. PQ did not affect this gene, which is one of the important genes involved in male fertility, at the concentrations studied; instead, geraniol in the presence of a low amount of PQ could modulate the expression of this gene. The histopathology results revealed that all sperm parameters, including sperm count, motility, and morphology, decreased after exposure to PQ. After gavage with geraniol in the J+PQ 0.5 and J+PQ 2.5 groups, there was no improvement in sperm morphology or parameters. Therefore, geraniol was not able to improve sperm parameters. Oral administration of PQ to male Wistar rats caused moderate to severe disturbances and changes in the testicular parameters of male rats, including decreased sperm count, motility, and normal morphology over time (29). A low sperm count, a high percentage of nonmotile sperm, and morphological abnormalities caused by exposure to PQ can cause infertility. Several studies in animals and humans exposed to environmental toxins have shown the negative effects of these toxins on semen quality, concentration, motility, and sperm morphology. Primary morphological defects, such as headless sperm, are also associated with reduced fertility (30, 31). These toxins may have estrogenic effects that in turn cause changes in the hypothalamic-pituitary-gonadal (HPG) axis, damage to sperm DNA, and epigenetic changes in sperm (32).

In this study, changes were observed in all histopathological parameters in the high-concentration PQ group, whereas no changes were observed in certain parameters within the low-concentration PQ group; notably, co-treatment with geraniol attenuated these toxic alterations. Fathi et al. reported that intraperitoneal administration of paraquat at doses of 10, 15, and 20 mg/kg over two weeks resulted in a marked reduction in various cell types within the seminiferous tubules in treated groups (5). This suggests that PQ exerts a dose-dependent cytotoxic effect on the testicular tissue.

Acknowledgements

The authors gratefully acknowledge the facilities and assistance offered by the Department of Anatomical Sciences at the Babol University of Medical Sciences and the Cell and Molecular Biology Lab at the Sari Agricultural Sciences and Natural Resources University.

Conflict of interest

The authors declare that they have no conflicts of interest. The authors declare that they have no known competing financial interests or personal relationships that could appear to influence the work reported in this paper.

Funding

The present paper was supported by Fatemeh Moradian's grant at Sari Agricultural Sciences and Natural Resources University.

Authors' contributions

Masoud Ghanbari: Methodology, Formal analysis, Data curation and writing original draft; Fatemeh Moradian: Writing, review and editing, Supervision, Project administration,

Conceptualization; Zahra Babazadeh: Project administration, Conceptualization, Review and editing of final version; Leila Begum Hijazian: Conceptualization, Review and editing of final version.

Ethics Approval and Consent to Participate

The animal experiments in this study were conducted in accordance with the national guidelines for the care and use of laboratory animals. Therefore, the study protocol was reviewed and approved by the Departmental Research Committee of the Faculty of Animal and Fisheries Sciences, Sari Agricultural Sciences and Natural Resources University, which confirmed that the experimental procedures met ethical and welfare standards. All experimental protocols in this study were reviewed and approved by the Institutional Animal Care and Ethics Committee of the Faculty of Animal Sciences, Sari Agricultural Sciences and Natural Resources University (Approval No. IR. SANRU.03-1403-02). All efforts were made to minimize discomfort and distress to the animals.

References

1. . Lindsay TJ, Vitrikas KR. Evaluation and treatment of infertility. Am Fam Physician. 2015;91(5):308-14. Erratum in: Am Fam Physician. 2015;92(6):437.
2. Babakhanzadeh E, Nazari M, Ghasemifar S, Khodadadian A. Some of the Factors Involved in Male Infertility: A Prospective Review. Int J Gen Med. 2020;13:29-41.
3. Suntres ZE. Role of antioxidants in paraquat toxicity. Toxicology. 2002;180(1):65-77.
4. Bora S, Vardhan GSH, Deka N, Khataniar L, Gogoi D, Baruah A. Paraquat exposure over generation affects lifespan and reproduction through mitochondrial disruption in C. elegans. Toxicology. 2021;447:152632.
5. Fathi N, Hossinipanah M, Haji Hossini M, Ranjbar A. Effects of paraquat on testicular histomorphometry of male rats. Biologic Forum. 2015;7(2):573-5.
6. Sutyarso M, Kanedi A. Impact of herbicide exposure on seminal parameters among oil palm plantation workers in Lampung province, Indonesia. Am J Biomed Res. 2014; 2(4):83-7.
7. Zain A. The evaluation of the toxic effect of paraquat and its mechanism of action on reproductive system of male rats, Thesis, Universiti Sains Malaysia, 2007; Penang. http://eprints.usm.my/9548/.
8. Ranjbar A. Evidence of oxidative damage in paraquat toxicity, Zahedan J Res Med Sci. 2014;16(12):1-8.
9. Wasiu A, Abdulfatai A. Toxic effects of paraquat dichloride leachate on testes and sperm parameters of male wistar rats. Int J Anat. Res. 2019;7(1.3):6274-9.
10. D'Souza UJ, Narayana K, Zain A, Raju S, Nizam HM, Noriah O. Dermal exposure to the herbicide paraquat results in genotoxic and cytotoxic damage to germ cell in the male rat. Folia Morphologica 2006;65(1):6-10.
11. Agarwal A, Virk G, Ong C, du Plessis SS. Effect of oxidative stress on male reproduction. World J Mens Health. 2014;32(1):1-17.
12. Asadi N, Bahmani M, Kheradmand A, Rafieian-Kopaei M. The Impact of Oxidative Stress on Testicular Function and the Role of Antioxidants in Improving it: A Review. J Clin Diagn Res. 2017;11(5):IE01-IE05.
13. Nwafor J, Uduma Ukpai C, Okechukwu J, Onwe Uchewa O, Ekaikite O, Ikpeze S. Biotherapeutic sufficiency of virgin coconut oil on PQ-mediated reproductive dysfunction. J Anatom Soci India. 2021; 70(2):106-112.
14. Chen W, Viljoen AM. Geraniol - A review of a commercially important fragrance material. South African J Botany 2010; 6(4):643-651.
15. Yu B, Huang Z. Variations in Antioxidant Genes and Male Infertility. Biomed Res Int. 2015;2015:513196.
16. Glorieux C, Zamocky M, Sandoval JM, Verrax J, Calderon PB. Regulation of catalase expression in healthy and cancerous cells. Free Radic Biol Med. 2015;87:84-97.
17. Kamali FS, Shahrooz R, Najafi GHR, Razi M. Ameliorative Effect of Crocin on Sperm Parameters and In Vitro Fertilization in Mice

under Oxidative Stress Induced by Paraquat. Int J Fertil Steril. 2020;13(4):307-314.
18.Ioulianos A, Sismani C, Fourouclas N, Patroclou T, Sergiou C, Patsalis PC. A nation-based population screening for azoospermia factor deletions in Greek-Cypriot patients with severe spermatogenic failure and normal fertile controls, using a specific study and experimental design. Int J Androl. 2002;25(3):153-8.
19. O'Flynn O'Brien KL, Varghese AC, Agarwal A. The genetic causes of male factor infertility: a review. Fertil Steril. 2010;93(1):1-12.
20. Colaco S, Modi D. Genetics of the human Y chromosome and its association with male infertility. Reprod Biol Endocrinol. 2018;16(1):14.
21. Sharp L, Cardy AH, Cotton SC, Little J. CYP17 gene polymorphisms: prevalence and associations with hormone levels and related factors. a HuGE review. Am J Epidemiol. 2004;160(8):729-40.
22. Imai T, Globerman H, Gertner JM, Kagawa N, Waterman MR. Expression and purification of functional human 17 alpha-hydroxylase/17,20-lyase (P450c17) in Escherichia coli. Use of this system for study of a novel form of combined 17 alpha-hydroxylase/17,20-lyase deficiency. J Biol Chem. 1993;268(26):19681-9.
23. Povey AC, Clyma JA, McNamee R, Moore HD, Baillie H, Pacey AA, Cherry NM; Participating Centres of Chaps-uk. Modifiable and non-modifiable risk factors for poor semen quality: a case-referent study. Hum Reprod. 2012;27(9):2799-806.
24. Rubio-Riquelme N, Huerta-Retamal N, Gómez-Torres MJ, Martínez-Espinosa RM. Catalase as a Molecular Target for Male Infertility Diagnosis and Monitoring: An Overview. Antioxidants (Basel). 2020;9(1):78.
25. Alizadeh S, Anani-Sarab G, Amiri H, Hashemi M. Paraquat induced oxidative stress, DNA damage, and cytotoxicity in lymphocytes. Heliyon. 2022;8(7):e09895.
26. Black AT, Gray JP, Shakarjian MP, Laskin DL, Heck DE, Laskin JD. Increased oxidative stress and antioxidant expression in mouse keratinocytes following exposure to paraquat. Toxicol Appl Pharmacol. 2008;231(3):384-92.
27. Lei Y, Fu P, Jun X, Cheng P. Pharmacological Properties of Geraniol - A Review. Planta Med. 2019;85(1):48-55.
28. Pavan B, Dalpiaz A, Marani L, Beggiato S, Ferraro L, Canistro D, et al. Geraniol Pharmacokinetics, Bioavailability and Its Multiple Effects on the Liver Antioxidant and Xenobiotic-Metabolizing Enzymes. Front Pharmacol. 2018;9:18.
29. Ofoego UC, Ekwujuru EU, Nwakanma A, Mbagwu IS, Nweke EO, Anibeze CIP. Protective and ameliorating effects of methanolic seed extract of Mucuna Pruriens on PQ induced testicular damage. Adv Life Sci Technol. 2018;63:8-16.
30. Venkatesh S, Pharm M, Gurdeep Singh M, Prasad Gupta N, Kumar R, Deecaraman M, Dada R. Correlation of sperm morphology and oxidative stress in infertile men. Iran J Reprod Med. 2009;7:29-34.
31. Schumacher J, Moll HD. Collection of semen. In: Schumacher J, Moll HD, editors. A Manual of Equine Diagnostic Procedures. Jackson, WY, US, Teton New Media, 2011.
32. Pizzorno J. Environmental Toxins and Infertility. Integr Med (Encinitas). 2018;17(2):8-11.
33. Deepananda Ashoka KHM and De Silva WA. Mechanism of Paraquat Action Shows Interference in Spermatogenesis and Epididymal Maturation of Sperm in Mice. J Biol. 2013;1(3): 67-76.